

Endodontic Treatment of the Mandibular First Molar with Six Roots Canals – Two Case Reports and Literature Review

JORGE N.R. MARTINS¹, CRAIG ANDERSON²

ABSTRACT

The most common configuration of the mandibular first molar is the presence of two roots and three root canals. The objective of this work is to present two rare anatomic configurations with six root canals on two mandibular left first molars diagnosed during endodontic therapy. Root canal therapy was performed using a dental operating microscope. Ultrasonic troughing in the grooves in between the mesial root canals and in between the distal root canals was able to show the middle root canals. Large samples population characterization researches and systematic reviews were unable to detect a single case of six root canals configuration in a mandibular first molar in their investigations. Although it is a rare configuration, a six root canal configuration is possible to be found in the mandibular first molar. Three different pulp chamber configurations are possible to be found. Two or three roots may be present and the root configuration more common in the mesial root is the Type 8 and Type 12 for the distal root. Some concepts about the required technique to approach these cases are also debated.

Keywords: Endodontic therapy, Molar, Root canal anatomy, Root canal preparation

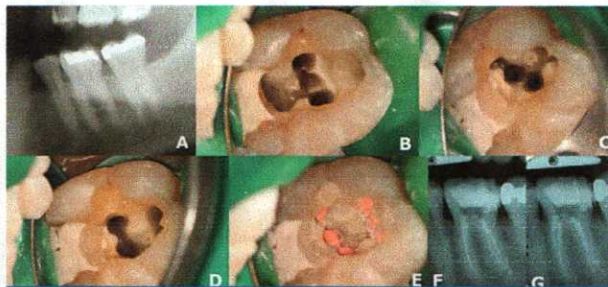
CASE REPORT #1

A 41-year-old Caucasian male was referred to an endodontic appointment for treatment of the mandibular left first molar (tooth 36). The patient had a chief complaint of spontaneous pain, and increasing pain to temperature variations in the mandibular left side. A clinical and a radiograph examination revealed an amalgam filling on the occlusal surface of the mandibular left first molar and a carious lesion on the distal portion of the tooth [Table/Fig-1a]. No periodontal pockets were present and the mobility was within the physiological limits. The reaction to the ice sensibility test was an intense pain that remained present for more than one minute. The adjacent teeth had a normal response to this test. The diagnosis of irreversible pulpitis on tooth 36 was made. The clinical condition was explained; the endodontic treatment was proposed and accepted.

The tooth was anaesthetized with an inferior alveolar nerve block (1.8 ml of 4% articaine with 1:200,000 epinephrine) (Artinibs, Inibs, Spain), rubber dam isolation was obtained, the amalgam filling and decay were removed and the proper access cavity was achieved. The examination of the pulp chamber floor utilizing a dental operating microscope (Opmi Pico, Carl Zeiss Surgical, Germany) was able to easily identify four canals (mesiobuccal, mesiolingual, distobuccal and distolingual). After canal identification and negotiation, the working length was determined by electronic apex locator (Root ZX II, Morita, USA). All mesial root canals had 22 mm and the distals had 21 mm. The mechanical instrumentation was performed with the Protaper Universal NiTi rotary files (ProTaper Universal, Dentsply Maillefer, Switzerland) as instructions of the manufacturer. All the instrumentation was performed with a continuous irrigation with 5.25% sodium hypochlorite. A closer look after root canal instrumentation was able to detect two grooves, one connecting the mesial root canals and a second one connecting the distal root canals. The two grooves were opened by troughing with #2 ProUltra ultrasonic tip (ProUltra, Dentsply Maillefer, USA). Two extra canals were detected (middle mesial and middle distal). These root canals were prepared in the same manner as the other four canals [Table/Fig-1b-1d]. From the data collected clinically and radiographically, it was possible to understand that this case had a three roots configuration with a Gulabivala Type 9 (3-1) configuration on the mesial root while the two distal roots had a Vertucci Type 1 (1-1) in

one of the roots and a Vertucci Type 2 (2-1) configurations in the other.

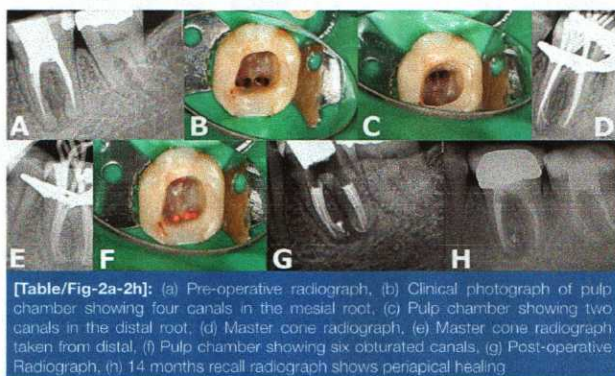
Because of the time limitation the therapy was finished in two appointments. The root canals were dried and a paste of calcium hydroxide (Ultracal, Ultradent, USA) was used as intracanal medication. Cavit (Cavit W, 3M ESPE, Germany) was used as a provisional restorative filling between visits. At the second appointment, a final irrigation protocol which included 17% EDTA irrigation followed by a final rinse with sodium hypochlorite was performed. The obturation technique chosen was the continuous wave of condensation technique and AH plus (AH Plus, Dentsply, Germany) was used as sealer [Table/Fig-1e-g]. The pulp chamber was restored provisionally with Cavit temporary filling. The tooth was scheduled for permanent restoration. Although it was not possible to bring back the patient to a proper one year recall, the patient mentioned, during the recall attempt contact, that he remains symptoms free.



[Table/Fig-1a-1g]: (a) Initial panoramic radiograph. Partial view of the mandibular left side. (b) Pulp chamber view after full instrumentation. Three mesial root canals can be seen. (c) Distolingual and middle distal canals can be seen in the distolingual root. (d) Single canal in the distobuccal root. (e) Pulp chamber view after root canal obturation. (f) Final radiograph after root canal obturation. (g) Final radiograph taken from distal

CASE REPORT #2

A 37-year-old Caucasian female of eastern European descent reported to a private endodontic practice with complaint of slight discomfort in the lower left quadrant. She reported having endodontic therapy approximately two years before by her general dentist. The radiographic examination revealed that the mandibular



[Table/Fig-2a-2h]: (a) Pre-operative radiograph, (b) Clinical photograph of pulp chamber showing four canals in the mesial root, (c) Pulp chamber showing two canals in the distal root, (d) Master cone radiograph, (e) Master cone radiograph taken from distal, (f) Pulp chamber showing six obturated canals, (g) Post-operative Radiograph, (h) 14 months recall radiograph shows periapical healing

left first molar (tooth 36) had previous endodontic therapy and periapical pathology [Table/Fig-2a]. Clinical examination revealed mild pain to percussion and palpation as well as moderate pain to biting. No increased periodontal probings or clinical fractures were noted. All adjacent teeth were found to be normal to all endodontic test. A diagnosis of previous endodontic therapy with symptomatic apical periodontitis was made. After explanation of the clinical condition, the treatment plan was accepted by the patient.

After proper anesthesia and rubber dam isolation, the existing composite filling was removed to expose the pulp chamber. All gutta-percha was removed from the previously treated canals (mesiobuccal, mesiolingual, distobuccal and distolingual) with ProTaper Universal Retreatment files (Tulsa Dentsply, USA). Upon inspection of the pulpal floor utilizing a dental operating microscope (Opmi Pico, Carl Zeiss Surgical, Germany) a distinct groove was noted running between the mesiobuccal and mesiolingual canals. Troughing of this groove with a #2 ProUltra ultrasonic tip (ProUltra, Dentsply Maillefer, USA) revealed two other canals (MM1/MM2) were apparent [Table/Fig-2b,c]. This case had a two roots configuration with a Gulavibala Type 11 (4-2) configuration in the mesial root and presented a Vertucci Type 4 (2-2) in the distal one. From here on the clinical procedures were very similar to Case Report #1 [Table/Fig-2d,e]. A 14 months recall radiograph shows, although with an incomplete obturation, a satisfactory periapical healing [Table/Fig-2f-h]. The patient remains asymptomatic.

DISCUSSION

The main purpose of endodontic therapy is to maintain the tooth function in absence of pain, thru the disinfection and obturation of the root canal system. The inability to correctly understand the tooth's anatomical configuration and the inability to identify all the root canals for subsequent disinfection and obturation may lead to endodontic treatment failure [1]. The root canal configuration has a strong ethnical influence [2]. Several investigations have already been conducted on several populations on the root canal anatomy of the mandibular first molar. On those studies it is possible to understand that the incidence of the middle mesial canal ranges from 1% in the North American population [3] to 10.8% in the Burmese population [4]. The incidence of the middle distal root canal ranges from 0.7% in the Burmese population [4] to 1.7% in Turkish population [5], although some studies were not able to identify a single case of a middle distal canal in their population samples. A systematic review [2] on the anatomy of the mandibular first molar with a combined sample of 18.781 teeth from in vivo and in vitro studies was unable to detect a single sample with six root canals.

The available knowledge on the six root canal configurations for the mandibular first molar comes from a very limited number of case reports. An extensive search was conducted in Pubmed electronic database, and for the best knowledge of the authors, prior to this work, only ten case reports of mandibular first molars with six, or more, root canals are available in the literature [6-14]. In the overall analysis of the limited number of reported cases (already including the two reported in the present work) it is possible to understand that three different pulp chamber anatomies are possible to be found in six root canal configurations: three mesial and three distal root canals (six reported cases), four mesial and two distal root canals (two cases) and two mesial and four distal root canals (three cases). Regarding the anatomy, the most usual root configuration in the mesial root is the Vertucci Type 8 (3-3) and in the distal root the most usual root configuration is the Gulavibala Type 12 (3-2) configuration. The number of roots range from two to four roots, and each root may present different morphologies. The resume of this case reports is presented in [Table/Fig-3].

In this paper, we present two different types of six root canals configurations. Both root canal orifices disposition on the pulp chamber floor have already been described. But due to the high variability of these types of anatomies, the reported cases on this

Reference	Country	Ethnicity	Gender	Age	Mesial Canals	Distal Canals	Root configuration
Martínez-Berná [6]	Spain	Caucasian	Female	22	3	3	Mesial root with a Vertucci Type 8 (3-3) and a distal root with a Gulavibala Type 12 (3-2)
Martínez-Berná [6]	Spain	Caucasian	Female	22	3	3	Mesial root with a Vertucci Type 8 (3-3) and a distal root with a Gulavibala Type 9 (3-1)
Reeh [7]	USA	N/A	Male	23	4	3	N/A
Ghoddusi [8]	Iran	N/A	Female	30	2	4	Two mesial roots, both Vertucci Type 1 (1-1), and two distal roots, one Type 1 (1-1) and one Vertucci Type 8 (3-3)
Aminsobhani [9]	Iran	N/A	Female	30	4	2	Mesial root with a Gulavibala Type 11 (4-2) and a distal root with a Vertucci Type 2 (2-1)
Ryan [10]	USA	N/A	Female	52	3	3	Mesial root with a Vertucci Type 8 (3-3) configuration and a distal root with Gulavibala Type 12 (3-2)
Gutpa [11]	India	N/A	Female	38	3	3	Both mesial and distal roots with a Gulavibala Type 12 (3-2) configuration
Baziar [12]	Iran	N/A	Male	42	2	4	A mesial root with a Vertucci Type 4 (2-2) configuration and a distal with a Gulavibala Type 11 (4-2) configuration.
Hasan [13]	Pakistan	N/A	N/A	N/A	3	3	Both mesial and distal roots with a Gulavibala Type 12 (3-2) configuration
Sinha [14]	India	N/A	Female	18	2	4	Mesial root with a Vertucci Type 4 (2-2) and a distal root with a Gulavibala Type 11 (4-2)
Present work Case #1	Portugal	Caucasian	Male	33	3	3	Mesial root with a Gulavibala Type 9 (3-1) and two distal roots, one Vertucci Type 1 (1-1) and one Type 2 (2-1)
Present work Case #2	USA	Caucasian	Female	37	4	2	Mesial root with a Gulavibala Type 11 (4-2) and a distal root with a Vertucci Type 4 (2-2)

[Table/Fig-3]: Mandibular first molar with six and seven root canals case reports available in Pubmed electronic database

paper also show some new features. As is the case of a three roots morphology on Case Report #1. This case has a Gulabivala Type 9 (3-1) root configuration on the mesial root while the distal roots presents a Vertucci Type 1 (1-1) and a Vertucci Type 2 (2-1) configurations. The second reported case has a Gulabivala Type 11 (4-2) configuration on the mesial root and presents a Vertucci Type 4 (2-2) in the distal, which is a quite similar anatomy when compared to Aminsobhani case [9].

In most of the cases, the information required to perform a correct root canal anatomy diagnosis is collected using clinical and radiographic findings. A recent report from Sinha et al., [14] is the only case that uses the computed cone beam tomography (CBCT) technology as a diagnostic method. Due to the increased radiation exposure, the benefits of its use must out weights the risks. Due to the limitation of the two-dimension nature of conventional radiographic techniques, the three dimensional images of CBCTs may be beneficial to perform a perfect diagnosis on complex anatomies such as multi-canal systems or Dens Invaginatus cases, or to pathologies diagnosis such as root resorptions, periapical pathosis or even root fractures [15]. In both cases reported on this paper, it was possible to accomplish the treatment without requiring any more diagnostic exams; such is the case of CBCT scans.

Regarding the techniques used to approach these cases some points are important to remind. The over-instrumentation should be avoided at all cost in cases with multiple canal configurations to minimize the chance of root weakness in cases where three, and sometimes more, canals have to be prepared in a single root [16]. Due to the complex root canal nature of these cases, both thermo-plastic root canal obturation techniques [16] and passive ultrasonic irrigation, which has been documented as capable to improve irrigation effects [17], may be useful to overcome the isthmus and depressions, many times present, in the roots.

CONCLUSION

Although it is an uncommon finding, a six root canal configuration is possible to be present in the mandibular first molar. These two case reports contributes to a better knowledge of the mandibular first molar anatomy with a presentation of two different configurations with six root canals which is a rare configuration on this tooth with limited information available. Exploring the groves in between root

canals is recommended, and unexpected root canals may be found in that area.

REFERENCES

- [1] Wolcott J, Ishley D, Kennedy W, Johnson S, Minnich S, Meyers J. A 5 yr clinical investigation of second mesiobuccal canals in endodontically treated and retreated maxillary molars. *J Endod.* 2005;31(4):262-64.
- [2] de Pablo O, Estevez R, Sanchez M, Heilborn C, Cohenca N. Root anatomy and canal configuration of the permanent mandibular first molar: a systematic review. *J Endod.* 2010;36(12):1919-31.
- [3] Vertucci FJ. Root canal anatomy of the human permanent teeth. *Oral Surg.* 1984;58(5):589-99.
- [4] Gulabivala K, Aung TH, Alavi A, Ng YL. Root and canal morphology of Burmese mandibular molars. *Int Endod J.* 2011;34(5):359-70.
- [5] Caliskan M, Pehlivan Y, Sepetcioglu Figen S, Turkun M, Tuncer S. Root canal morphology of human permanent teeth in a Turkish population. *J Endod.* 1995;21(4):200-04.
- [6] Martinez-Berna A, Badanelli P. Mandibular first molars with six root canals. *J Endod.* 1985;11(8):348-52.
- [7] Reeh ES. Seven canals in lower first molar. *J Endod.* 1998;24(7):497-99.
- [8] Ghodduji J, Naghavi N, Zarei M, Rohani E. Mandibular first molar with four distal canals. *J Endod.* 2007;33(12):1481-83.
- [9] Aminsobhani M, Shokouhinejad N, Ghabraei S, Bolhari B, Ghorbanzadeh A. Retreatment of a 6-canal mandibular first molar with four mesial canals: a case report. *Iran Endod J.* 2010;5(3):138-40.
- [10] Ryan J, Bowles W, Baisden M, McClanahan S. Mandibular first molar with six separated canals. *J Endod.* 2011;37(6):878-80.
- [11] Gupta S, Jaiswal S, Arora R. Endodontic management of permanent mandibular left first molar with six root canals. *Contemp Clin Dent.* 2012;3(Suppl 1):S130-S133. doi: 10.4103/0976-237X.95124.
- [12] Baziari H, Daneshvar F, Mohammadi A, Jafarzadeh H. Endodontic management of a mandibular first molar with four canals in a distal root by using cone-beam computed tomography: a case report. *J Oral Maxillofac Res.* 2014;5(1):e5.
- [13] Hasan M, Rahman M, Saad N. Mandibular first molar with six root canals: a rare entity. *BMJ Case Rep.* 2014;2014:bcr2014205253. doi: 10.1136/bcr-2014-205253.
- [14] Sinha N, Singh B, Langaliya A, Mirdha N, Huda I, Jain A. Cone beam computed tomographic evaluation and endodontic management of a rare mandibular first molar with four distal canals. *Case Rep Dent.* 2014;2014:306943. doi: 10.1155/2014/306943. Epub 2014 Dec 1
- [15] Patel S, Durack C, Abella F, Roig M, Shemesh H, Lambrechts P, et al. European Society of Endodontology position statement: The use of CBCT in Endodontics. *Int Endod J.* 2014;47(6):502-04.
- [16] Martins JN. Endodontic treatment of a maxillary first molar with seven root canals confirmed with cone beam computer tomography – case report. *J Clin Diagn Res.* 2014;8(6):13-15.
- [17] Macedo RG, Wesselink PR, Zaccaro F, Fanali D, van der Sluis LWM. Reaction rate of NaOCl in contact with bovine dentine: effect of activation, exposure time, concentration and pH. *Int Endod J.* 2010;43(12):1108-15.

PARTICULARS OF CONTRIBUTORS:

1. Doctor of Dental Surgery, University of Lisbon (POR), Inter PG Endodontics at New York University (USA), Certified member of European Society of Endodontology, Department of Endodontics of Instituto de Implantologia, Lisbon (POR).
2. Doctor of Dental Medicine, University of Mississippi (USA), Endodontic Certificate at New York University (USA), Member of American Association of Endodontics, Private Practice, Biloxi Mississippi (USA).

NAME, ADDRESS, E-MAIL ID OF THE CORRESPONDING AUTHOR:

Dr. Jorge N. R. Martins,
Instituto de Implantologia of Lisbon, Av.Columbano Bordalo Pinheiro, 50 – 5º e 6º, 1070-064 Lisboa - Portugal.
E-mail : jnr_martins@yahoo.com.br

FINANCIAL OR OTHER COMPETING INTERESTS: None.

Date of Submission: Oct 28, 2014
Date of Peer Review: Feb 27, 2015
Date of Acceptance: Mar 02, 2015
Date of Publishing: Apr 01, 2015